

Sudden cardiac death risk in contact sports increased by myocarditis: a case series

Grégoire Massoulié^{1,2}, Baptiste Boyer³, Vincent Sapin⁴, Frédéric Jean¹, Marius Andronache^{1,2}, Michel Peoc'h⁵, Guillaume Clerfond^{1,2,6}, and Romain Eschalier^{1,2,6*}

¹Cardiology Department, CHU Clermont-Ferrand, Rue Montalembert, 63000 Clermont-Ferrand, France; ²Université Clermont Auvergne, CHU Clermont-Ferrand, CNRS, SIGMA Clermont, Institut Pascal, F-63000 Clermont-Ferrand, France; ³Institute of Legal Medicine, CHU Clermont-Ferrand, Clermont-Ferrand, France; ⁴Biochemistry Department, CHU Clermont-Ferrand, Clermont-Ferrand, France; ⁵Department of Pathology, CHU St-Etienne, France; and ⁶INI-CRCT F-CRIN, Nancy, France

For the podcast associated with this article, please visit <https://academic.oup.com/ehjcr/pages/podcast>.

Received 17 June 2020; first decision 15 July 2020; accepted 25 October 2020

Background

Myocarditis is a known cause of sudden cardiac death of the athlete. The impact of direct chest trauma in at-risk sports or activities in patients with a history of myocarditis has never been demonstrated or studied. We report herein two cases of life-threatening ventricular arrhythmia secondary to non-penetrating blunt chest trauma while playing contact sports.

Case summary

The first patient, a 26-year-old man described a brief loss of consciousness after having received blunt impact to the chest (typical intensity) while playing a rugby match. The loss of consciousness was total and proceeded by rapid and regular palpitations. He had a history of viral myocarditis 10 years prior with a fibrotic sequela in the inferolateral wall on cardiac magnetic resonance imaging (left ventricular ejection fraction 71%). Right apical ventricular pacing induced a sustained monomorphic ventricular tachycardia reproducing the patient's symptoms. A subcutaneous implantable cardioverter-defibrillator was implanted. The second patient is a 22-year-old professional rugby player with no known notable history. During a match, a direct blow to the chest wall was followed by a cardiac arrest. A ventricular fibrillation was cardioverted to pulseless electrical activity. Patient died despite cardiopulmonary resuscitation. An autopsy identified a myocardial sequela of fibrosis with no acute inflammatory remodeling compatible with a previous myocarditis.

Discussion

Myocarditis may increase the risk of life-threatening ventricular arrhythmias caused by blunt impact to the chest, particularly in contact sports. Screening and prevention measures should be considered to reduce this risk.

Keywords

Myocarditis • Sudden death • Ventricular arrhythmia • Case series

Learning points

- Myocarditis may increase the risk of life-threatening arrhythmia related to chest blunt trauma.
- A dedicated somatic assessment and protection measure aims to reduce chest contact should be considered in sports at risk.

* Corresponding author. Tel: +33 473 751 410, Fax: +33 473 754 730, Email: reschalier@chu-clermontferrand.fr

Handling Editor: Sabiha Gati

Peer-reviewers: David Niederseer and Danny van de Sande

Compliance Editor: Max Sayers

Supplementary Material Editor: Vassilios Parisi Memtsas

© The Author(s) 2021. Published by Oxford University Press on behalf of the European Society of Cardiology.

This is an Open Access article distributed under the terms of the Creative Commons Attribution Non-Commercial License (<http://creativecommons.org/licenses/by-nc/4.0/>), which permits non-commercial re-use, distribution, and reproduction in any medium, provided the original work is properly cited. For commercial re-use, please contact journals.permissions@oup.com

Introduction

Myocarditis, predominantly in its acute phase but also in its chronic form due to sequelae, is a known cause of sudden cardiac death (SCD) in athletes (5–25%).^{1–4} Symptoms of acute myocarditis are variable: from silent inflammatory response to non-specific viral syndrome, chest pain, dyspnoea, or ventricular arrhythmia and SCD. The condition may be difficult to diagnose; myocarditis can go undiagnosed, in particular, in elite athletes who seem to have an increased risk of viral infection susceptible to viral infections.⁵ They cumulate risk factor increasing exposure to pathogen (international events and worldwide travelling) and factors that may impair immune system (sleep deprivation, extreme environment, high intensity exertion, or training). Biological tests (e.g. ultra-sensitive troponin) and cardiac magnetic resonance imaging (MRI) are central to the diagnosis of myocarditis,^{5,6} increasing the number and accuracy of diagnoses, as well as the reliability of a prognosis. However, the long-term risk of life-threatening ventricular arrhythmias (LTVA) is poorly understood. Subsequent events may occur long after the initial episode.⁷ Furthermore, the incidence of ventricular arrhythmia during contact sports in patients with a history of myocarditis has not been demonstrated or studied.

We report here on two cases of syncope, in one instance followed by SCD, secondary to a non-penetrating blunt chest trauma during sports activity (rugby) in patients with sequelae of myocarditis.

Timeline

	Age	Myocarditis history	Previous symptoms	Clinical manifestation	Management
Case 1	26	2011	Yes, syncope/ palpitations	Palpitations and syncope after a chest tackle during a rugby game	Hospitalization in intensive care unit. Inducible ventricular tachycardia. Subcutaneous internal cardioverter defibrillator and ventricular tachycardia (VT) ablation.
Case 2	21	Unknown	No	ventricular fibrillation (VF)—sudden death after a chest tackle during a rugby game	Immediate cardiac pulmonary resuscitation (CPR), no resuscitation. Autopsy demonstrated a previous myocarditis without other sudden death explanation.

Case series

Case 1

A 26-year-old man presented brief loss of consciousness while playing a rugby match (semi-professional competitive level).

His medical history was marked by a myocarditis 10 years prior based on (i) an elevation of cardiac enzymes along with electrocardiographic changes (diffuse ST-elevation), (ii) presence of coxsackie virus B IgM, and (iii) identification by cardiac MRI (CMR, 1.5 T) of acute myocarditis on a delayed enhancement sequence of epicardial hyperintensity lesions in the inferolateral wall. Following anti-inflammatory therapy (aspirin 1000 mg every 8 h for 3 weeks) and

during follow-up, the patient reported no symptoms, and an exercise stress test was normal (absence of ischaemia or LTVA). Cardiac MRI performed 11 months after the acute episode revealed a fibrotic scar in the inferolateral wall along with myocardial wall thinning and normal left ventricular ejection fraction (LVEF) (71%). As recommended,^{8,9} sports were contraindicated for 6 months following the acute myocarditis event, after which he was able to resume competitive sports. The patient was followed annually with clinical, electrocardiographic, and trans-thoracic echocardiographic (TTE) assessments. There was no recurrence of myocarditis or cardiac symptoms, and no evidence of arrhythmic events. The patient was not taking any medication.

The current syncopal episode occurred after the patient received a tackle with blunt impact (typical intensity) directly on the chest. The loss of consciousness was total and proceeded by rapid and regular palpitations. Return to consciousness was rapid without post-ictal confusion, and no injury was recorded. The patient was evacuated from the field for medical evaluation. He had been describing similar symptoms for several years, exclusively upon direct chest wall impact. Because of this history, the patient was admitted to the hospital emergency unit. Haemodynamics were stable, and the clinical cardiovascular and neurological examination was normal. Laboratory testing revealed moderately elevated troponins I_c at 35 ng/L (high sensitive troponin I_c, normal range 0–14 ng/L) and creatine phosphokinase 381 U/L (normal 20–200 U/L). The 12-lead electrocardiogram revealed a normal QT interval (QT_c: 442 ms), a repolarization similar to that previously described (i.e. negative Q waves in the posterior

and lateral leads), fragmented QRS in the inferior leads, and left-axis deviation (-70°) (Figure 1).

A new CMR (1.5 T) was performed (Figure 2) and found to be superimposable on the previous image, as well as a similar TTE. Prolonged monitoring of the heart rate did not reveal the presence of LTVA, ventricular ectopy, or other arrhythmias. An electrophysiological study was carried out (class IC, level C).¹⁰ Right apical ventricular pacing induced a sustained monomorphic ventricular tachycardia (VT) originating from the left ventricular (LV) lateral wall (212 ms, i.e. 283 b.p.m.) and loss of consciousness, reproducing the patient's on-field symptoms (Figure 1). Return to sinus rhythm was achieved with an antitachycardia pacing burst.

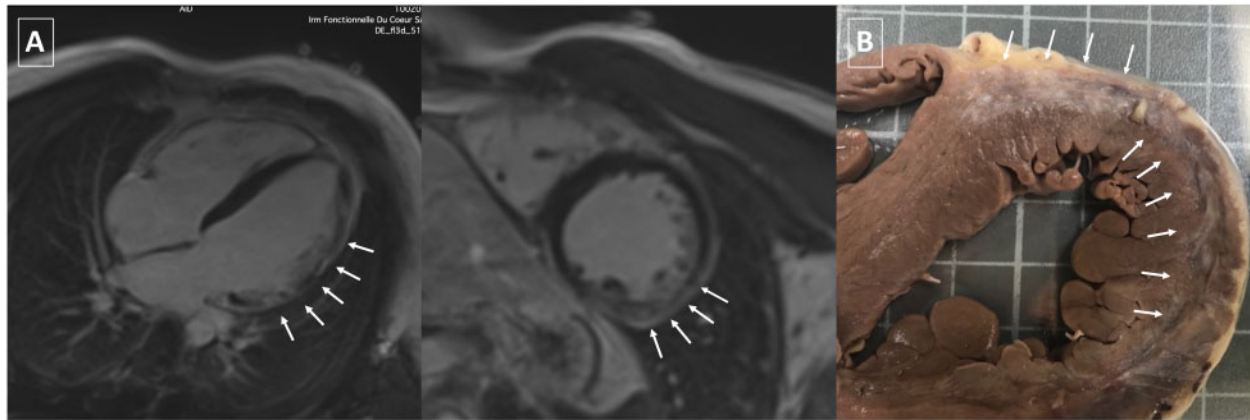


Figure 1 Confirmation of myocardial fibrosis in both rugby players displaying life-threatening ventricular arrhythmias. (A) Cardiac magnetic resonance imaging (1.5 T) of Case 1 rugby player. The presence of a sequela of myocarditis (arrows) can be observed on the inferolateral wall with myocardial thinning. (B) Macroscopic image after fixation in formalin. Presence of an area of old whitish-coloured fibrosis mainly involving the anterior ventricular septum, the anterior and lateral aspect of the left ventricle, at the epicardial and myocardial levels.

This young patient was implanted with a subcutaneous implantable cardioverter-defibrillator (S-ICD)¹⁰ and was treated with beta-blockers (bisoprolol 2.5 mg o.d.; heart rhythm at discharge: 39 b.p.m.).⁶ To reduce the burden of arrhythmic events, a VT ablation with a sub-xyphoidian epicardial approach was performed 1 month later. Critical VT isthmuses were located within the myocardial scar tissue (Figure 2). During follow-up, the patient remained asymptomatic with no VT recurrence recordings in S-ICD follow-up. Considering the rugby practice and the risk of chest blunt trauma, he was dissuaded from competitive-level playing. Due to patient intolerance and the absence of inducible VT after ablation and during stress test, beta-blockers were discontinued.

Case 2

A 21-year-old man, professional rugby player, with no known personal or family history of cardiovascular diseases and LVTA/SCD presented a cardiac arrest. During a rugby match, he was tackled with a direct blow to the chest wall and lost consciousness temporarily but was able to reach the edge of the field with the help of trainers. In the locker room, the patient suffered several brief losses of consciousness followed by cardiopulmonary arrest. Upon arrival of the medical emergency services, the patient was unconscious and gasping for air. The low-flow period was poorly recognized and deemed to have lasted a few minutes. The electrocardiogram (ECG) recorded by the portable defibrillator (Figure 3) revealed ventricular fibrillation. External cardioversion (one biphasic shock of 300 J) allowed a return to agonal rhythm measured at 35 b.p.m. Haemodynamics remained unstable and despite 47 min of resuscitation, the patient died on site.

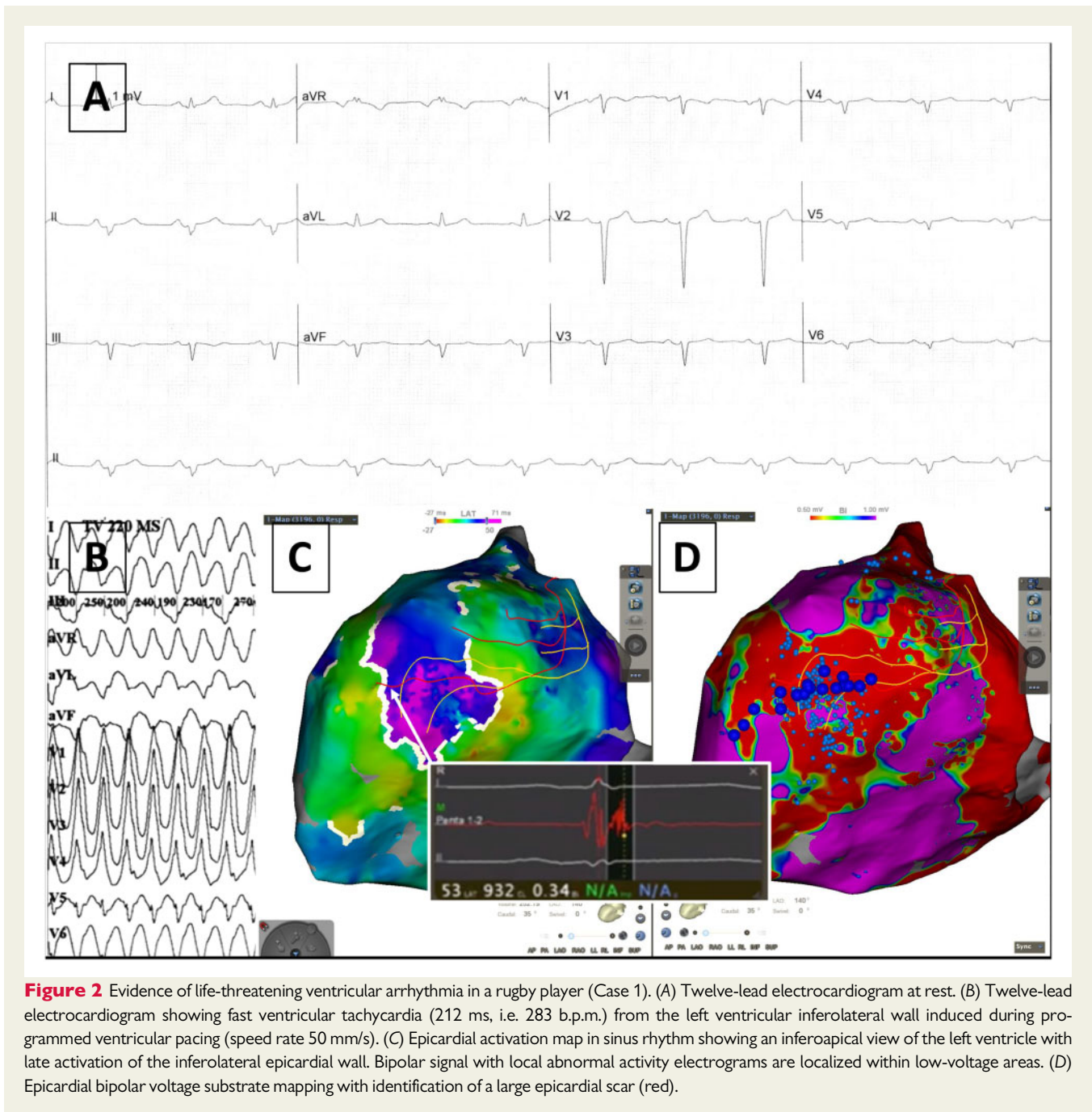
An autopsy was performed. Histological study of the heart identified epicardial and myocardial sequelae of fibrosis in the anterior interventricular septum extending over the anterior, lateral, and lower aspects of the myocardium with no acute inflammatory remodelling (Figure 2). This lesion was compatible with a sequela of myocarditis, the age of which cannot be determined. There was no coronary lesion or dissection nor valve injury. Left ventricular dimensions and mass were normal

for the age and practice of high-level competitive sport. Moreover, in the patient's personal history obtained from his family and general practitioner, no indication of prior myocarditis could be identified. Ten months earlier, a cardiological assessment (ECG and TTE) had not found any signs contraindicating the practice of competitive rugby.

Discussion

This report describes the case of two high-performance athletes suffering a non-penetrating blunt chest trauma associated with the occurrence of LTVA due to a chronic sequela of myocarditis. In contrast to the classically described *commotio cordis*, these two episodes of ventricular arrhythmias were associated with underlying myocardial scarring.

Commotio cordis is a rare phenomenon defined by the occurrence of an LTVA induced by a non-penetrating chest trauma.¹¹ At sufficient intensity, the shock wave is capable of producing a depolarization of the myocardial cells primarily via the activation of potassium ATP channels.¹² Occurring at the peak of the T wave, i.e. an electrically vulnerable period of cardiac repolarization, this depolarization can induce a sustained ventricular arrhythmia, often difficult to control and recurrent.¹³ The phenomenon can be immediate with a rapid and complete loss of consciousness, although ~20% of patients are able to continue their activity for a few seconds^{13,14} (cf. Case 2). Although very rare, *commotio cordis* has been described in sports with chest blows (baseball, lacrosse, etc.).¹⁵ Reported cases and series indicate that the phenomenon affects mostly young athletes. The prevalence of *commotio cordis* appears to be higher in the USA than in Europe (21.6× higher) due to the more common practice of competitive contact sports among North American youth and also to the absence of a dedicated registry in Europe.^{14,16} A recent review of the literature found only 215 reported cases (160 autopsies performed) of *commotio cordis* with an estimated incidence of 3–6% of SCD occurring during sporting activity.^{17,18} However, underreporting is a possibility, considering the poor survival rates, the circumstances of occurrence, and the definitions used. The diagnosis is above all one of exclusion,



and the post-SCD aetiological workup, including autopsy, must seek differential diagnoses even if the circumstances are highly suggestive.

Myocarditis is a cardiac condition most commonly of viral origin. Due to the diversity of its clinical manifestations, it is difficult to assess the incidence in the general population. The occurrence of cardiac arrest appears to increase with exertion and in high-performance athletes.¹⁹ Current consensus dictates that sports activity is contraindicated for the ensuing 3–6 months following an episode of myocarditis.¹⁹ The resumption of training and competitions is authorized on condition of normal LVEF, negative serum biomarker, and absence of arrhythmias on exertion and at rest. Demonstration

of persistent abnormal cardiac fibrosis on CMR may be considered as an additional SCD risk factor without justifying additional restrictions.⁹

A review of the literature identified a similar case of a soccer player who suffered a cardiac arrest secondary to a direct chest wall trauma and the presence of a sequela of myocarditis.²⁰ This and the present two cases share similar mechanisms and aetiology. However, the soccer player exhibited mild-biventricular dysfunction and was thus at increased risk of ventricular arrhythmias.

To date, myocardial scarring has not been associated with an increased risk of arrhythmia in the event of *commotio cordis*. The

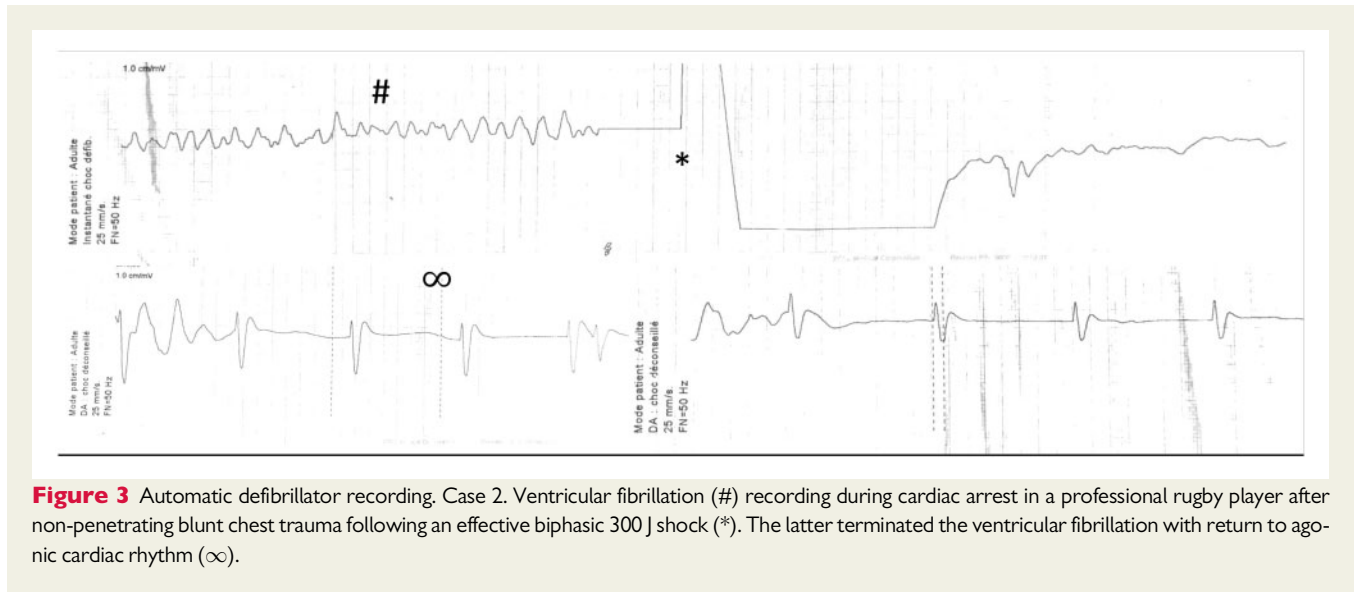


Figure 3 Automatic defibrillator recording. Case 2. Ventricular fibrillation (#) recording during cardiac arrest in a professional rugby player after non-penetrating blunt chest trauma following an effective biphasic 300 J shock (*). The latter terminated the ventricular fibrillation with return to agonic cardiac rhythm (∞).

factors associated with arrhythmias include type of mechanical stimulus, stimulus intensity, site of impact, and the timing of the impact in the cardiac cycle (peak of the T wave). Prevention is based on chest-protection equipment and changes in rules of play of at-risk sports without a complete elimination of the risk of blunt chest trauma. Professional athletes may be more exposed than amateurs through repeated training and the intensity of the contacts. However, given the nature of the sport, the occurrence is also frequent in non-professional rugby.²¹ In both cases presented, chest blows are part of the game and the intensities were not unusual for experienced players. The presence of myocarditis may have promoted both the onset and sustained nature of a ventricular arrhythmia (see Case 2).

Currently, an ECG is required for participation in high-level competitive sports. We believe that certain sports with chest wall impact should require a thorough and systematic cardiological assessment. In the USA as in France, the eligibility assessment for the practice of a high-level sport is not compulsory and depends on each federation.²² Such evaluation is advisable and encompasses a cardiological assessment with at the very least a clinical examination, an ECG, and a TTE in the event of an abnormality during the previous examinations. Cardiac MRI is not systematic although it would seem advisable to broaden the indication. With regard to amateur athletes practicing a sport with risk of chest blows, the presence of an abnormality on ECG/TTE⁹ or a prior cardiovascular history should always lead to a myocardial CMR. For professional athletes practicing such sports, cardiac CMR should be systematically performed. The risk of non-ischæmic myocardial injury, such as myocarditis has increased with the COVID-19 pandemic,^{23–25} with 7–40% of patients hospitalized or admitted to intensive care unit presenting with virus-related acute myocarditis.^{23,26} The underlying mechanism of injury has not yet been identified and high-quality data are not available. Due to the suspected high prevalence of COVID-19 cardiac injury, a specific screening (serologic test and CMR) should strongly be considered before the start of the 2020/2021 season.

The history of our two patients suggests that chest contact sports may share a higher risk of rhythmic complications in cases of

myocardial scarring. Using CMR late gadolinium enhancement mapping (LGE), asymptomatic focal myocardial LGE has been identified in up to 30% of athletes and non-athletes.²⁷ An association with ventricular arrhythmia has not been documented, but subepicardial LV LGE has been associated with ventricular arrhythmias and appears not to be a benign condition.²⁸ These lesions are typical of post-myocardial scarring but may also be associated with non-ischæmic cardiomyopathies (arrhythmogenic dysplasia). These few data are insufficient to support a recommendation to discontinue competitive sport based on the mere existence of cardiac fibrosis. However, practitioners should be alert to the presence of a ventricular LGE and examine such patients further to determine the aetiology of cardiac lesions and the arrhythmic risk from scars, which will guide recommendations on sports activities.

Beyond the somatic assessment, there remains the question of the risk of death or serious trauma in high-level sports. The recent modification to harmful high-tackle rules in World Rugby encouraging a systematic sanction of the referees is aimed at reducing the incidence of whiplash and concussion.²⁹ It may be insufficient to only penalize 'high tackle' (head and neck) since no impact on the risk of LVTA secondary to chest trauma will be observed. Some federations are currently testing limiting tackles to below the hips in non-professional leagues. The present case descriptions may motivate a reflection on further player protection measures that should not be limited to rugby. In particular, during the current COVID-19 pandemic, more studies in larger populations of professional and amateur athletes should be performed to evaluate the potentially higher risk of LVTA associated with sequelae of myocarditis. Such data would be necessary to guide modifications of the minimal examination tests and athletics rules.

Conclusion

The occurrence of chest wall trauma during sports activities is frequent and, under very specific conditions, can be associated with

severe ventricular arrhythmia. A sequela of myocarditis increases the risk of lethal ventricular arrhythmias following blunt chest trauma. Further studies and systematic CMR assessments should be performed to evaluate the potentially higher risk of LVTA and the benefit of and an adaptation of the rules, in terms of health and medico-economic aspects.

Lead author biography



Grégoire Massoulié is an electrophysiologist at Clermont-Ferrand University Hospital. He completed his residency in Clermont-Ferrand and his fellowship in arrhythmia management at Bordeaux University Hospital (IHU LIRYC, Pr Haïssaguerre).

Supplementary material

Supplementary material is available at *European Heart Journal - Case Reports* online.

Acknowledgements

We thank Mr Pierre Pothier for the editing of the manuscript.

Slide sets: A fully edited slide set detailing this case and suitable for local presentation is available online as [Supplementary data](#).

Consent: The authors confirm that written consent for submission and publication of this case report including images and associated text has been obtained from the patients or next of kin in line with COPE guidance.

Conflict of interest: None declared.

Funding: None declared.

References

1. Maron BJ, Udelson JE, Bonow RO, Nishimura RA, Ackerman MJ, Mark ENA et al. Eligibility and disqualification recommendations for competitive athletes with cardiovascular abnormalities: task force 3: hypertrophic cardiomyopathy, arrhythmogenic right ventricular cardiomyopathy and other cardiomyopathies, and myocarditis. *Circ Am Heart Assoc* 2015;**132**:e273–e280.
2. Maron BJ, Epstein SE, Roberts WC. Causes of sudden death in competitive athletes. *J Am Coll Cardiol* 1986;**7**:204–214.
3. Maron BJ, Haas TS, Ahluwalia A, Rutten-Ramos SC. Incidence of cardiovascular sudden deaths in Minnesota high school athletes. *Heart Rhythm* 2013;**10**:374–377.
4. Maron BJ, Haas TS, Ahluwalia A, Murphy CJ, Garberich RF. Demographics and epidemiology of sudden deaths in young competitive athletes: from the United States National Registry. *Am J Med* 2016;**129**:1170–1177.
5. Halle M, Binzenhöfer L, Mahrholdt H, Johannes Schindler M, Esefeld K, Tschöpe C. Myocarditis in athletes: a clinical perspective. *Eur J Prev Cardiol* 2020; 2047487320909670.
6. Mahrholdt H, Goedecke C, Wagner A, Meinhardt G, Athanasiadis A, Vogelsberg H et al. Cardiovascular magnetic resonance assessment of human myocarditis: a comparison to histology and molecular pathology. *Circulation* 2004;**109**:1250–1258.
7. Peretto G, Sala S, Rizzo S, Palmisano A, Esposito A, Cobelli FD et al. Ventricular arrhythmias in myocarditis: characterization and relationships with myocardial inflammation. *J Am Coll Cardiol* 2020;**75**:1046–1057.
8. Pelliccia A, Fagard R, Bjørnstad HH, Anastassakis A, Arbustini E, Assanelli D et al. Recommendations for competitive sports participation in athletes with cardiovascular disease: a consensus document from the Study Group of Sports Cardiology of the Working Group of Cardiac Rehabilitation and Exercise Physiology and the Working Group of Myocardial and Pericardial Diseases of the European Society of Cardiology. *Eur Heart J* 2005;**26**:1422–1445.
9. Pelliccia A, Solberg EE, Papadakis M, Adami PE, Biffi A, Caselli S et al. Recommendations for participation in competitive and leisure time sport in athletes with cardiomyopathies, myocarditis, and pericarditis: position statement of the Sport Cardiology Section of the European Association of Preventive Cardiology (EAPC). *Eur Heart J* 2019;**40**:19–33.
10. Piori SG, Blomström-Lundqvist C, Mazzanti A, Blom N, Borggrefe M, Camm J et al. 2015 ESC Guidelines for the management of patients with ventricular arrhythmias and the prevention of sudden cardiac death: the task force for the management of patients with ventricular arrhythmias and the prevention of sudden cardiac death of the European Society of Cardiology (ESC). Endorsed by: Association for European Paediatric and Congenital Cardiology (AEPC). *Eur Heart J* 2015;**36**:2793–2867.
11. Maron BJ, Link MS, Wang PJ, Estes NA. Clinical profile of *commotio cordis*: an underappreciated cause of sudden death in the young during sports and other activities. *J Cardiovasc Electrophysiol* 1999;**10**:114–120.
12. Link MS, Wang PJ, VanderBrink BA, Avelar E, Pandian NG, Maron BJ et al. Selective activation of the K(+) (ATP) channel is a mechanism by which sudden death is produced by low-energy chest-wall impact (*Commotio cordis*). *Circulation* 1999;**100**:413–418.
13. Maron BJ, Poliac LC, Kaplan JA, Mueller FO. Blunt impact to the chest leading to sudden death from cardiac arrest during sports activities. *N Engl J Med* 1995;**333**:337–342.
14. Cooper S, Woodford NW, Maron BJ, Harris KM, Sheppard MN. A lethal blow to the chest as an underdiagnosed cause of sudden death in United Kingdom Sports (Football, Cricket, Rugby). *Am J Cardiol* 2019;**124**:808–811.
15. Maron BJ, Ahluwalia A, Haas TS, Semsarian C, Link MS, Estes NAM. Global epidemiology and demographics of *commotio cordis*. *Heart Rhythm* 2011;**8**:1969–1971.
16. Solberg EE, Embrå Bl, Börjesson M, Herlitz J, Corrado D. *Commotio cordis*—under-recognized in Europe?: a case report and review. *Eur J Cardiovasc Prev Rehabil* 2011;**18**:378–383.
17. Maron BJ, Gohman TE, Kyle SB, Estes NAM, Link MS. Clinical profile and spectrum of *commotio cordis*. *JAMA* 2002;**287**:1142–1146.
18. Lupariello F, Di Vella G. The role of the autopsy in the diagnosis of *commotio cordis* lethal cases: review of the literature. *Leg Med* 2019;**38**:73–76.
19. Harmon KG, Asif IM, Maleszewski JJ, Owens DS, Prutkin JM, Salerno JC et al. Incidence, cause, and comparative frequency of sudden cardiac death in national collegiate athletic association athletes: a decade in review. *Circulation* 2015;**132**:10–19.
20. Zeldetz V, Greenberg S, Zeller L, Zahger D, Shalev A. *Commotio Cordis* in a professional soccer player: value of MRI in unraveling myocardial damage. *Circ Cardiovasc Imaging* 2018;**11**:e007848.
21. Gastin PB, McLean O, Spittle M, Breed RVP. Quantification of tackling demands in professional Australian football using integrated wearable athlete tracking technology. *J Sci Med Sport* 2013;**16**:589–593.
22. Yeomans C, Kenny IC, Cahalan R, Warrington GD, Harrison AJ, Hayes K et al. The incidence of injury in amateur male rugby union: a systematic review and meta-analysis. *Sports Med* 2018;**48**:837–848.
23. Knight DS, Kotecha T, Razvi Y, Chacko L, Brown JT, Jeetley PS et al. COVID-19: Myocardial injury in survivors. *Circulation* 2020;**142**:1120–1122.
24. Zhou F, Yu T, Du R, Fan G, Liu Y, Liu Z et al. Clinical course and risk factors for mortality of adult inpatients with COVID-19 in Wuhan, China: a retrospective cohort study. *Lancet* 2020;**395**:1054–1062.
25. Kim I-C, Kim JY, Kim HA, Han S. COVID-19-related myocarditis in a 21-year-old female patient. *Eur Heart J* 2020;**41**:1859–1859.
26. Madjid M, Safavi-Naeini P, Solomon SD, Vardeny O. Potential effects of coronaviruses on the cardiovascular system: a review. *JAMA Cardiol* 2020;**5**:831.
27. Banks L, Altaha MA, Yan AT, Dorian P, Konieczny K, Deva DP et al. Left ventricular fibrosis in middle-age athletes and physically active adults. *Med Sci Sports Exerc* 2020;**52**:2500–2507.
28. Schnell F, Claessen G, Gerche AL, Bogaert J, Lentz P-A, Claus P et al. Subepicardial delayed gadolinium enhancement in asymptomatic athletes: let sleeping dogs lie? *Br J Sports Med* 2016;**50**:111–117.
29. World Rugby Laws—World Rugby's Law Education Web Site. <https://laws.worldrugby.org/?domain=9&language=en> (23 March 2020).